



UDC: 616.831-089:617.539

lype Cherian (Prof.)

Department of Neurosurgery, College of Medical Sciences, Bharatpur, Chitwan, Nepal

## CISTERNOSTOMY

Cisternostomy is opening the basal cisterns to atmospheric pressure. This technique helps to reduce the intracranial pressure in severe head trauma as well as multiple other conditions when the so called malignant brain swelling troubles the surgeon. We are elaborating the proposed physiology of how cisternostomy works and the surgical anatomy of this procedure. This novel technique has the scope of changing a lot of current trends in Neurosurgery.

**Keywords:** Cisternostomy, severe head injury, membrane of Lilliequist, Virchow Robin Spaces

### The current scenario

The severely head injured patient is usually handled by the junior residents and the Critical care physicians in most settings over the world. Advancements in microsurgery have not been put to practice in head trauma surgery and the surgical option is over hundred years old, done mostly by inexperienced residents. Advancements in critical care has to an extent decreased the mortality in severe head trauma, but there are huge lacunae in the surgical treatment for this unique and complex problem.

### How does Cisternostomy work?

The brain is surrounded by CSF. The CSF is produced in the lateral, third and fourth ventricle at a rate of about 500 ml per day. This CSF passes from the fourth ventricle to the cisterns through the foramen of Magendie and Luschka. The cisterns contain about 120 ml of CSF. The current theory states that this CSF gets absorbed into the major venous sinuses through arachnoid granulations 6 (Fig. 6).

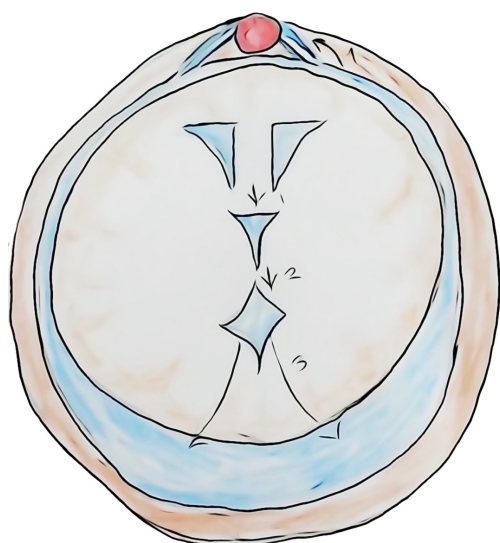


Figure 6 – Normal CSF flow pathway

However, the Glymphatic system has proven that CSF from the cisterns (and not from the ventricles)

does communicate with the parenchyma through the Virchow Robin spaces 7, 8.

This has implications for waste removal from a very much metabolically active brain, failing which Neurodegenerative diseases like Alzheimer sets in 9.

However for cisternostomy this has different implications. The most common phenomenon in severe head trauma is a diffuse traumatic subarachnoid hemorrhage. This causes the cisternal pressure to go up with respect to the "intra brain pressure". CSF will shift into the brain parenchyma through the Virchow Robin spaces and the brain would swell up and become non-compliant (Fig. 7).

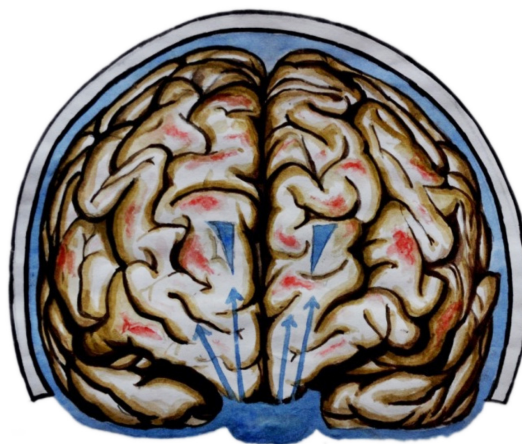


Figure 7 – Raised cisternal pressure due to the traumatic subarachnoid hemorrhage shifts CSF into the brain causing raised intracerebral pressure

Since the cisterns and the brain communicate, it would be possible to decrease the pressures in both these compartments by opening the cisterns to the atmospheric pressure. This will produce a backshift of the CSF through the Virchow Robin spaces and will result in decreased intra-brain pressure. On the other hand, decompressive hemicraniectomy opens a window above and the brain stretches causing stretch injury to the axons. (Fig. 8 and 9).

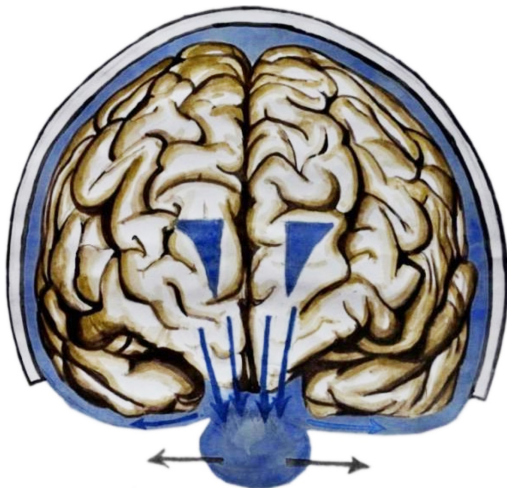


Figure 8 – Opening of the cisterns reverses the cisternal pressure gradient reversing the CSF flow back into the cisterns decreasing the brain pressure

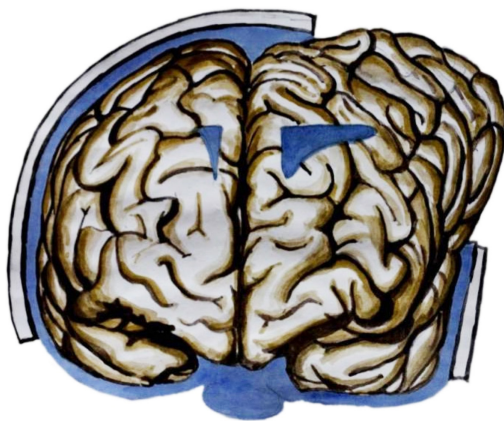


Figure 9 – Decompressive hemicraniectomy allows extracranial herniation leading to further deterioration due to axonal stretch and altered blood flow dynamics

The drainage of CSF from the cisterns with a drain for the next 5 days will also be beneficial for the fact that the lactate 10, tau 11 and free radicals 12 which would be present within the injured brain would be washed out and this would minimize the secondary damage.

**Surgical anatomy of Cisternostomy**

Opening cisterns in a tight brain is a difficult procedure. Retracting a tight and noncompliant brain is something which has been a problem for a century of Neurosurgical practice 1. However, the skullbase approaches provide an answer to this problem and takes one very near to the optico-carotid cistern in an extradural fashion.

The dura of the frontal lobes and the temporal lobes are very adherent to each other and the anterior clinoid process 2 can be considered to be “buried” between these two lobes. Opening up these lobes are very important to approaching the cisterns. However, the key to opening these lobes up is the right plane and this plane is provided by the correct incision of the orbitomeningeal band 3 (Fig. 1).

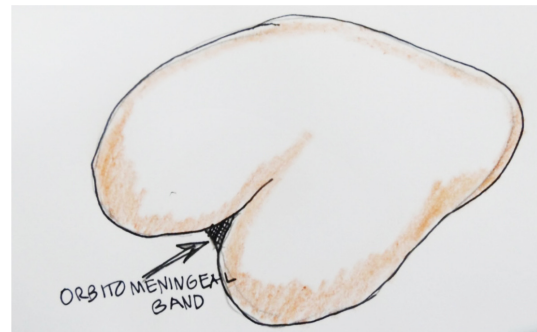

Figure 1 – Menigoorbital band

After a fronto-temporal craniotomy, the correct incision of the lateral menigo-orbital band results in a plane where one can separate the frontal dura over the anterior clinoid and the temporal dura over the lateral wall of the cavernous sinus resulting in uncovering the anterior clinoid process as well as opening the fold of the frontal and temporal lobe helping in a more direct lateral pathway to the cisterns (Fig. 2 and 3).

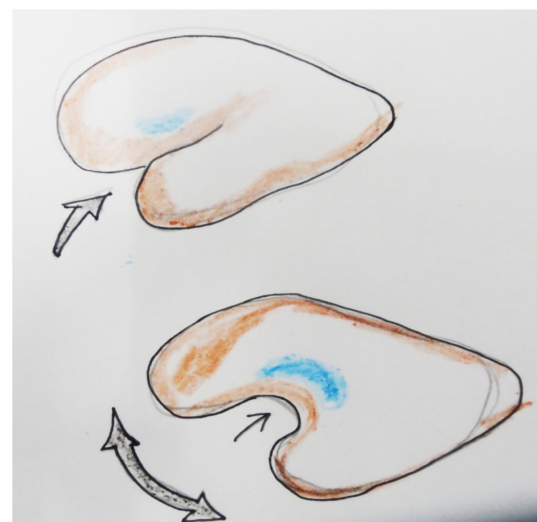


Figure 2 – Opening of meningo-orbital band and “unfurling” the brain to reach the basal cisterns

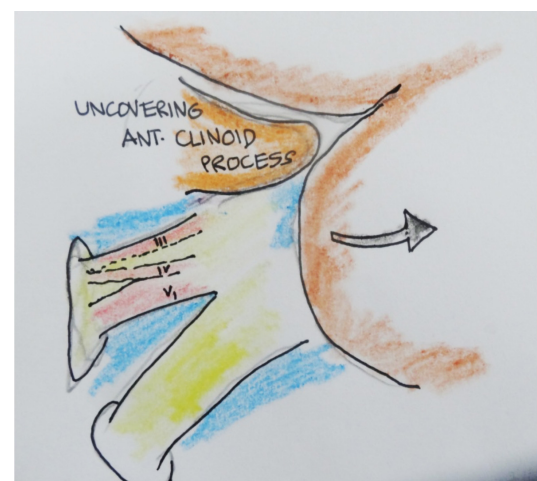


Figure 3 – Opening of the cavernous region and the anterior clinoid process



The uncovered anterior clinoid process can be removed easily with rongeurs. If the temporal dura is then separated over the cavernous sinus, and the frontal dura is lifted up, one can extradurally, reach to the base of the brain where the cisterns are. After this, a linear dural incision can be placed just above the optic nerve to make use of a lateral subfrontal corridor. Minimal to moderate brain retraction is necessary to reach the interoptic cistern. Usually there is a large amount of blood which comes out with this and if the pressure is very high, brain also may herniate. However, this maneuver gets the brain to be lax and then one can retract the arachnoid covering the opticocarotid cistern and let out the blood. This is the most important maneuver in Cisternostomy and for a beginner, all this steps may not be easy. If somebody has been doing decompressive hemicraniectomies, they can first position the patient, with the head slightly extended and turned to the opposite side about 15 degrees. Then they may rongeur the sphenoid ridge up to the superior orbital fissure and then open the dura as basal as possible. After this the same lateral subfrontal route may be employed to reach the interoptic cistern. Once they have the surgical experience with this and when very tense dura is encountered, the technique mentioned above may be useful.

Once the opticocarotid cisterns and the lateral carotid cisterns are opened, the brain becomes lax enough to open the membrane of Liliequist through one of these windows. The membrane of Liliequist 4,5 is a double layered membrane which acts like a curtain through which the third nerve and the posterior communicating artery traverses from the anterior cranial fossa to the posterior cranial fossa (Figure 4).

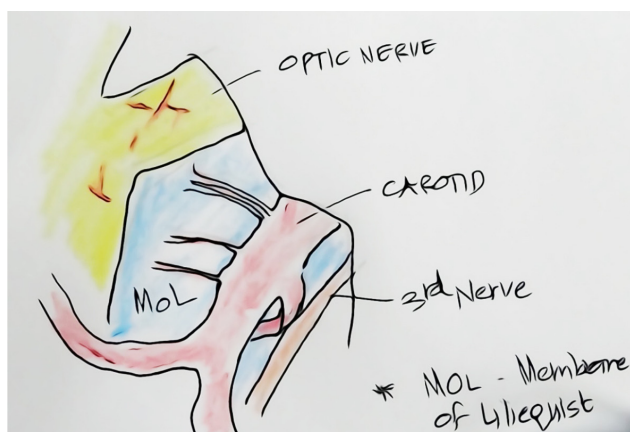


Figure 4 – Optico-carotid and the lateral carotid cisterns along with membrane of Liliequist

One can follow these structures and open the arachnoid around these to reach the basilar complex and the prepontine cistern as well as the interpeduncular cistern (Fig. 5).

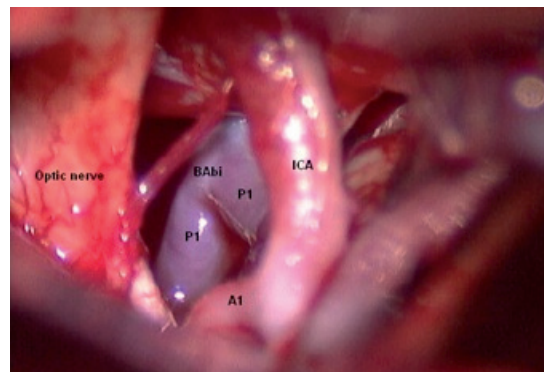


Figure 5 – Visualisation of basilar artery after opening the membrane of Liliequist

Sometimes the posterior clinoid process is very large and prevents opening of the membrane of Liliequist. In these instances, the posterior clinoid process may be drilled off after opening its dura. This may be done in the window between the carotid and the third nerve or in a very difficult scenario between the A1 segment of anterior cerebral artery, internal carotid artery and the optic nerve. This is an extremely advanced and difficult maneuver and should not be done unless one is experienced.

Once the prepontine cistern and the interpeduncular cistern is opened, the opened cisterns are irrigated copiously with normal saline and a catheter is placed in the prepontine cistern and continuously irrigated. Any small bleeding will be taken care of by this maneuver and the CSF drainage from the cisterns will be maintained for the next 5 days through the catheter. This catheter may also be used for intracranial pressure monitoring after closure.

## Discussion

The procedure of cisternostomy uses microsurgical principles to decrease the "intra - cerebral" pressure and reduce secondary damage. Although it is primarily useful in severe head trauma, other instances where intraoperative malignant brain edema, and edema in Intracerebral hemorrhage and subarachnoid bleeding will respond to opening cisterns. We believe that every neurosurgical residents and young neurosurgeons should be trained to access and open cisterns as well as how to handle the vessels within the cisterns as a part of their training.

## REFERENCES

1. Andrews RJ, Bringas JR. A review of brain retraction and recommendations for minimizing intraoperative brain injury. *Neurosurgery*. 1993 Dec;33(6):1052-63; discussion 1063-4.
2. Huynh-Le P, Natori Y, Sasaki T. Surgical anatomy of the anterior clinoid process. *J Clin Neurosci*. 2004 Apr;11(3):283-7.
3. Fukuda H, Evins AI, Burrell JC, Iwasaki K, Stieg PE, Bernardo A. The Meningo-Orbital Band: Microsur-

gical Anatomy and Surgical Detachment of the Membranous Structures through a Frontotemporal Craniotomy with Removal of the Anterior Clinoid Process. *J Neurol Surg B Skull Base*. 2014 Apr;75(2):125-32.

4. Brasil AV, Schneider FL. Anatomy of Lilliequist's membrane. *Neurosurgery*. 1993 Jun;32(6):956-60; discussion 960-1.

5. Lü J, Zhu XI. Microsurgical anatomy of Lilliequist's membrane. *Minim Invasive Neurosurg*. 2003 Jun;46(3):149-54.

6. Brodbelt A, Stoodley M. CSF pathways: a review. *Br J Neurosurg*. 2007 Oct;21(5):510-20.

7. Yang L, Kress BT, Weber HJ, et al. Evaluating glymphatic pathway function utilizing clinically relevant intrathecal infusion of CSF tracer. *Journal of Translational Medicine*. 2013;11:107. doi:10.1186/1479-5876-11-107.

8. Iliff JJ, Wang M, Liao Y, et al. A Paravascular Pathway Facilitates CSF Flow Through the Brain Parenchyma and the Clearance of Interstitial Solutes,

Including Amyloid  $\beta$ . *Science translational medicine*. 2012;4(147):147ra111. doi:10.1126/scitranslmed.3003748.

9. Wang JZ, Xia YY, Grundke-Iqbal I, Iqbal K. Abnormal hyperphosphorylation of tau: sites, regulation, and molecular mechanism of neurofibrillary degeneration. *J Alzheimers Dis*. 2013;33 Suppl 1:S123-39.

10. Lama S, Auer RN, Tyson R, Gallagher CN, To-manek B, Sutherland GR. Lactate Storm Marks Cerebral Metabolism following Brain Trauma. *The Journal of Biological Chemistry*. 2014;289(29):20200-20208. doi:10.1074/jbc.M114.570978.

11. Iliff JJ, Chen MJ, Plog BA, et al. Impairment of Glymphatic Pathway Function Promotes Tau Pathology after Traumatic Brain Injury. *The Journal of Neuroscience*. 2014;34(49):16180-16193. doi:10.1523/JNEUROSCI.3020-14.2014.

12. O'Connell KM, Littleton-Kearney MT. The role of free radicals in traumatic brain injury. *Biol Res Nurs*. 2013 Jul;15(3):253-63.

### ТҮЙІНДЕМЕ

*Iype Cherian (Prof.)*

*Department of Neurosurgery, College of Medical Sciences, Bharatpur, Chitwan, Nepal*

## ЦИСТЕРНОСТОМИЯ

Цистерностомия ауа қысымының негізгі қойнауларын ашады. Бұл техника ауыр бассүйек-ми жарақаты кезінде, сонымен қатар басқа да жағдайларда мидың қатерлі ісігіне операция жасаушы хирургтың жұмысын қиындатқан кезде интракраниалды қысымды азайтуға көмектеседі. Біз бұл процедурадағы цистерностомия және хирургиялық

анатомияның қалай жұмыс істеудегі ұсынылған физиологиясын жетілдіреміз. Бұл жаңа тәсілдің нейрохирургиялық емдеудегі тенденцияларды өзгертуге белгілі әсері бар.

**Негізгі сөздер:** цистерностомия, ауыр бас сүйек-ми зақымы, Lilliequist жарғақшасы, Вирхов-Робин кеңістігі.

### РЕЗЮМЕ

*Iype Cherian (Prof.)*

*Department of Neurosurgery, College of Medical Sciences, Bharatpur, Chitwan, Nepal*

## ЦИСТЕРНОСТОМИЯ

Цистерностомия открывает базальные цистерны для выравнивания с атмосферным давлением. Эта техника помогает уменьшить интракраниальное давление при тяжелой черепно-мозговой травме, а также при других различных случаях, когда злокачественный отек головного мозга осложняет работу оперирующего хирурга.

Мы совершенствуем предлагаемую физиологию того, как работает цистерностомия и хирургическую анатомию этой процедуры. Этот новый подход имеет определенное влияние на изменение тенденций в нейрохирургическом лечении.

**Ключевые слова:** цистерностомия, тяжелая черепно-мозговая травма, мембрана Lilliequist, Пространство Вирхова-Робина.