



UDC: 616.34-007.43-031:611.959

Farid Yudoyono (M.D.)<sup>1</sup>, Muhammad Zafrullah Arifin (M.D., Ph.D.)<sup>1</sup>,  
Farida Arisanti (M.D.)<sup>2</sup>, Shin Dong Ah (Prof., M.D.)<sup>3</sup>

Department of Neurosurgery, Faculty of Medicine Universitas Padjadjaran-Dr Hasan Sadikin General Hospital, Bandung, Jawa Barat, Indonesia<sup>1</sup>

Department of Physical Medicine and Rehabilitation, Faculty of Medicine Universitas Padjadjaran-Dr Hasan Sadikin General Hospital, Bandung, Jawa Barat, Indonesia<sup>2</sup>

Yonsei University College of Medicine, Seoul. Korea: Spine and Spinal cord Research Institute, Yonsei University College of Medicine<sup>3</sup>

## UNILATERAL PARTIAL HEMILAMINECTOMY AND DISCECTOMY DECREASED SURGICAL TIME AND HOSPITAL LENGTH OF STAY FOR LUMBAR DISC HERNIATED PATIENTS

**Objective.** To present the profiles of discectomy technique of Herniated Lumbar Disc through a unilateral Partial hemilaminectomy (UPHL) and to demonstrate its usefulness for herniated lumbar disc that significantly occupy the foraminal canal.

**Methods.** From April 2012 to June 2012, 24 herniated lumbar disc were approached with unilateral partial hemilaminectomy retrospectively.

**Results.** A total of 24 consecutive patients who underwent unilateral partial hemilaminectomy comprised male 14 and female 10 (1,4 :1), the mean age was 54 y.o. (21-68 years), with reflects to surgical level 2 patients involved Th 12-L 1, 12 patients involved lumbar 4-5, two patients involved L 3-4, and 6 patients involved L5-S1. In all cases, the herniated disc was removed totally without damaging thecal sac or roots. Neurological status showed improvement in all patients except three whose neurologic deficit slight changed. Surgical time was 179 minutes, hospital length of stay 5 days. Postoperative spinal stability was preserved during the follow-up period (in the mean 6 months) in all cases. Recurrence herniated disc did not develop during the follow-up period. Robinson Clinical outcome assesment good 21, fail 3.

**Conclusion.** Unilateral Partial hemilaminectomy combined with microsurgical technique provides sufficient space for the removal of foraminal herniated disc. The basic profiles of the herniated lumbar disc which can be removed through the unilateral Partial hemilaminectomy demonstrate its role for the surgery of the herniated lumbar disc in foraminal location, and it can decreased surgical time and hospital length of stay.

**Key words:** herniated lumbar disc, microsurgical unilateral partial hemilaminectomy

### Introduction

Yasargil et al in 1991 first describe the unilateral hemilaminectomy for the spinal cord tumor surgery. Advances in microsurgical technique and modern microsurgical equipment have added its usefulness to herniated lumbar disc surgery. Sporadic results of surgery for spinal cord herniated lumbar disc using a unilateral hemilaminectomy have been reported by many authors. Unilateral hemilaminectomy has more benefits with regard to postoperative spinal stability comparing with a total laminectomy. However, unilateral partial hemilaminectomy has not been a widely accepted surgical option for the removal of herniated lumbar disc. This may be because of surgeons' concerns about incomplete removal of the herniated disc or inadvertent thecal sac damage with the relatively narrow surgical corridor. [1, 2, 3]

In this study, we retrospectively investigated the profiles of herniated lumbar disc that could be removed through a unilateral partial hemilaminectomy. We would like to illuminate the role of unilateral partial hemilaminectomy for herniated lumbar disc that significantly occupy the foraminal intervertebralis. Some technical tips are also discussed for overcoming the narrow surgical corridor.

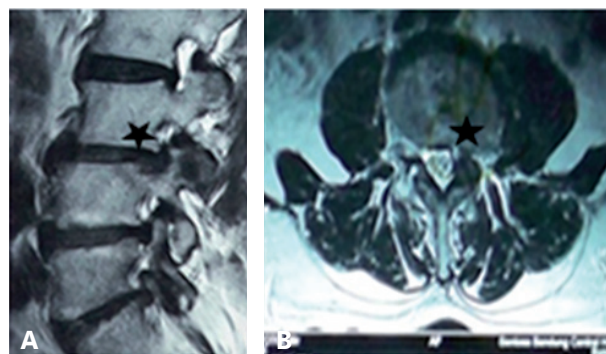


Figure 1 – A) MRI lumbar of herniated disc Sagittal View  
B) Herniated disc at foraminal Axial View (asterixis)

### Materials

Patients who presented to Severance Hospital, Yonsei University College of Medicine, Seoul, Korea, between April 2012 and June 2012 with one and two consecutive level of herniated lumbar disc in the foraminal intervertebralis, were removed through a unilateral partial hemilaminectomy between. Medial location that need extensive thecal sac retraction were excluded. The spinal level, location in the spinal canal,

visual analog scale and hospital length of stay, surgical time and robinson clinical outcome assesment was evaluated.

### Surgical methods

Patients were placed in the prone position under general anesthesia and the surgeries were performed by one neurospinal surgeon. Unilateral subperiosteal muscle dissection was performed and the lamina was exposed in a way similar to the techniques used for unilateral hemilaminectomy and discectomy. The dural sac was exposed by drilling the lamina, including the base of the spinous process, while preserving the facet joint. To overcome the narrow field of the unilateral hemilaminectomy, we employed several operative technical tips. Combining undercutting of the base of the spinous processes and oblique tilting of the operating table to the contralateral or ipsilateral side provided an adequate view for the extradural procedures. After removed of the flavum ligament, epidural fat and dural sac was expose, applying cottonoid to the upper and lower pole helps to prevent the excessive spread of blood clots into the spinal canal. We can slightly retracted the dural sac and nerve root medially to view the herniated disc. [4, 5]

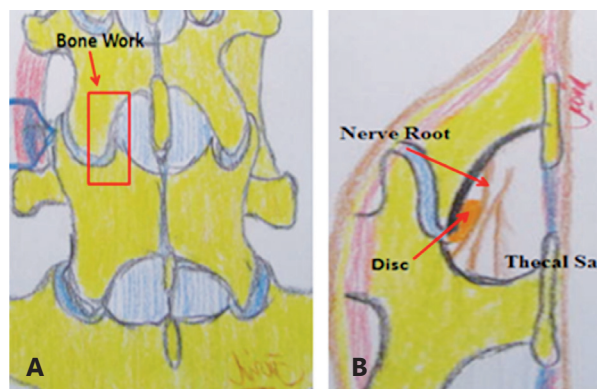


Figure 2 – A, B) Illustration of unilateral partial hemilaminectomy

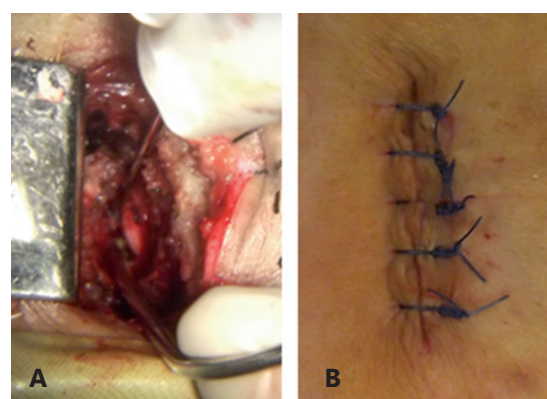


Figure 3 – A) Surgical view of unilateral partial hemilaminectomy showed Nerve root and dural sac  
B) Minimal (3 cm) Incision of surgical procedure

### Result

Twenty-four of foraminal herniated lumbar disc were removed through unilateral partial hemilaminectomy

(one patient had bilateral location). The characteristics of the herniated disc and its basic profiles are summarized (Table 1).

Table 1

#### Patients Demographic data

No	Age (y.o.)	Sex	Symptoms	VAS pre op	VAS post op	MRI	Pro-cedure	Surgical time (Minute)	Hospital length of stay (days)	Complication	Robinson Outcome scale
1	64	male	Myeloradiculopathy	6	2	Herniated disc L3-L4	UPHL	150	5	no	Good
2	62	male	Myeloradiculopathy	5	1	Herniated disc L3-4 and L4-5	UPHL	200	6	no	Good
3	56	male	Radiculopathy	4	3	Herniated disc L2-3	UPHL	216	6	skin infection	Good
4	52	female	radiculopathy	5	2	Herniated disc L5-S1	UPHL	320	5	no	Good
5	32	female	radiculopathy	6	2	Herniated disc L4-5	UPHL	190	5	no	Good
6	36	female	radiculopathy	7	2	Herniated disc L5-S1	UPHL	150	5	no	Good
7	43	female	radiculopathy	6	6	herniated disc L5-S1	UPHL	165	5	no	fair
8	21	male	Myeloradiculopathy	4	2	Herniated disc L4-5	UPHL	175	6	no	Good
9	50	male	radiculopathy	5	1	Herniated disc L4-5	UPHL	165	5	no	Good
10	54	female	radiculopathy	6	1	Herniated disc L4-5	UPHL	180	6	no	Good
11	61	male	radiculopathy	8	1	Herniated disc Th12-L1	UPHL	190	6	no	Good
12	67	male	radiculopathy	4	6	Herniated disc L4-5	UPHL	203	6	no	Good
13	56	male	Myeloradiculopathy	5	5	Herniated disc L3-L4	UPHL	150	5	no	fair



No	Age (y.o.)	Sex	Symptoms	VAS pre op	VAS post op	MRI	Pro- ce- dure	Surgi- cal time (Min- ute)	Hos- pital legth of stay (days)	Complication	Robinson Outcome scale
14	62	male	Myeloradiculopathy	6	1	Herniated disc L3-4 and L4-5	UPHL	165	6	no	Good
15	57	male	radiculopathy	6	2	Herniated disc L2-3	UPHL	155	6	no	Good
16	54	female	radiculopathy	6	2	Herniated disc L5-S1	UPHL	155	5	no	Good
17	68	female	radiculopathy	6	6	Herniated disc L4-5	UPHL	175	5	no	fair
18	55	female	radiculopathy	7	2	Herniated disc L5-S1	UPHL	166	5	no	Good
19	65	female	radiculopathy	7	1	herniated disc L5-S1	UPHL	180	5	no	Good
20	54	male	Myeloradiculopathy	7	1	Herniated disc L4-5	UPHL	190	6	no	Good
21	45	male	radiculopathy	8	1	Herniated dsic L4-5	UPHL	150	5	no	Good
22	66	female	radiculopathy	8	5	Herniated disc L4-5	UPHL	152	6	skin infection	Good
23	67	male	radiculopathy	8	4	Herniated disc Th12-L1	UPHL	165	6	no	Good
24	67	male	radiculopathy	9	4	Herniated disc L4-5	UPHL	190	6	no	Good

The patients consisted of 14 males and 10 females with a mean age of 54 years old (21-68) with reflects to surgical level 2 patients involved Th 12-L 1, 12 patients involved lumbar 4-5 , 2 patients involved L 3-4 , and 6 patients involved L5-S1. Postoperative neurological status showed improvement in all patients except three whose neurologic deficit slight changed. Surgical time was 179 minutes, hospital length of stay 5 days. Postoperative spinal stability was preserved during the follow-up period (6 months) in all cases. Recurrence herniated disc did not develop during the follow-up period. Robinson Clinical outcome assesment good 21, fail 3.

Visual analogue scale was improved in all patients except three, whose neurological deficit slightly changed. Complications, such as cerebrospinal fluid leakage, postoperative instability, and aggravation of neurological status, did not occur. The patient was observed without any surgical intervention, and the symptom was completely resolved during the hospital stay. The conventional bilateral laminectomy has been employed for surgical removal of herniated lumbar disc. It offers some convenience to neurospinal surgeons, such as widened exposure of the surgical fields. However, bilateral laminectomy also has disadvantages that can complicate postoperative outcomes. It produces overt spinal instability, leading to spinal deformity, epidural fibrosis, the absence of osseous protection for the spinal cord and postoperative axial pain. Well-recognized postlaminectomy kyphosis, especially in children, is commonly associated with instability.

## Discussion

Various operative techniques were developed to reduce postlaminectomy complications. Some authors presented advantages of laminoplasty in maintaining postoperative stability. However, the advantage of laminoplasty in maintaining postoperative stability is not considered because laminoplasty can still disrupt the posterior ligamentous structures on the dorsal spine.

The integrity of ligament flavum, supraspinous, and interspinous ligaments is known to be crucial for the dynamic stability of the spine. Unilateral partial hemilaminectomy avoids damage to the supraspinous and interspinous ligaments, and the paravertebral muscle of the opposite side. For this reason, unilateral partial hemilaminectomy results in less injury to the dynamic dorsal structures of the vertebral column compared with total laminectomy or even laminoplasty. Disadvantage of unilateral partial hemilaminectomy is a narrow surgical corridor formed by the spinous process and ipsilateral facet joint. This is the main reason that this procedure is still not widely accepted. [4, 6]

Our experience indicates that unilateral partial hemilaminectomy is useful for the removal of herniated lumbar disc in the intervertebral foraminal. All but three patient showed slightly neurological improvement. Most of the patients presented radiating pain symptoms. Analyses of data from the 24 cases revealed that however, there was ultimately no case of conversion to a total laminectomy. Since we adopted the unilateral partial hemilaminectomy for the removal of herniated lumbar disc, all consecutive cases of herniated lumbar disc have been removed with a unilateral partial hemilaminectomy. The distribution of the herniated lumbar disc was variable. [2, 6, 7]

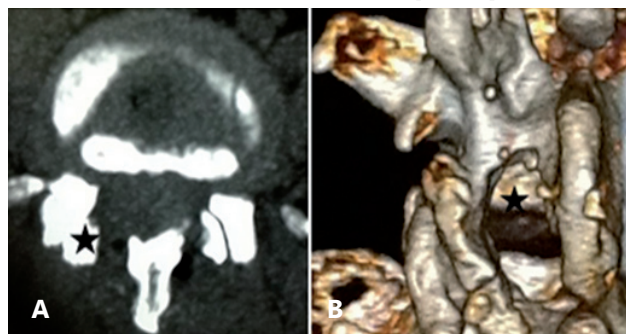


Figure 4 – A) Post operative Lumbar CT scan showed unilateral partial hemilaminectomy (asterix)  
B) Lumbar 3D CT showed bone worked (asterix)

Rehabilitation programs post unilateral partial hemilaminectomy of lumbar disk herniated could be delivered as early as possible due to preserve stability of the spine and faster recovery compared to other surgery approach. [8,9] Previous studies revealed that short term intensive rehabilitation programs could be started 4-6 weeks with range duration 6-12 weeks after spine surgery in lumbar disk herniated patients and shown functional status, faster decrease of pain, disability and return to work. [9, 10, 11]

Return to work times is depending on previous condition of the patient and physical requirement of the job. Higher functional disability, more intensive

pain, and poor motivation at 2 months after lumbar disk operation are risk factors for future loss of working time [13]. Early return to work is 3,3 days in preliminary study following an aggressive rehabilitation program initiated 1 day post spine surgery. [12]

### Conclusion

Unilateral partial hemilaminectomy combined with several microsurgical technique provides sufficient corridor for the removal of herniated lumbar disc. We recommend unilateral partial hemilaminectomy as a suitable surgical option for the removal of herniated disc in the foraminal intervertebralis.

### REFERENCES

1. Cai-xing, Shang-nao Xie, Yang Yu, Hong-jian Yang, Bin Wu. Unilateral hemilaminectomy for patients with intradural extramedullary tumors. *Journal of Zhejiang University-Science B (Biomedicine & Biotechnology)* 2011; 12:575-81.
2. Mony Benifla, Igor Melamed, Revital Barrely, Andrey AloushinbAnd Ilan Shelef, . Unilateral partial hemilaminectomy for disc removal in a 1-year-old child Case report. *J Neurosurg Pediatrics* 2008;2:133-5.
3. Yasargil MG, Tranmer, B.I., Adamson, T.E., Roth, P. Unilateral Partial Hemilaminectomy for the Removal of Extra- and Intramedullary Tumors and AVMs. *Advances and Technical Standards in Neurosurgery* 1991:113-32.
4. Dong Kyu Yeo. Soo Bin Im, Kwan Woong Park, Dong Seong Shin, Bum Tae Kim, Won Han Shin, Department of Neurosurgery, Soonchunhyang University Hospital, Bucheon, Korea. Profiles of Spinal Cord Tumors Removed through a Unilateral Hemilaminectomy. *J Korean Neurosurg Society* 2011;50 195-200.
5. A Cetin Sanoglu , H Bozkus. Unilateral hemilaminectomy for the removal of the spinal space-occupying lesions. *Minimally Invasive Neurosurg* 1997;40:74-7.
6. Amit Agrawa, Bhushan Wani. Modified posterior unilateral laminectomy for a complex dumbbell schwannoma of the thoracolumbar junction. *Acta Orthop Traumatol Turc* 2009;43:535-9.
7. Balak N. Unilateral partial hemilaminectomy in the removal of a large spinal ependymoma: case report and technical review. *Spine Journal* 2008.;8:1030-6.
8. Snyder, L.A., O'Toole, John., Eichholz, KM., Perez-Cruet, M.J., Fessler, Richard., The technological development of minimally invasive spine surgery. *BioMed Research International* 2014: 1-9
9. Ostelo, JG. et al. Rehabilitation following first-time lumbar disc surgery: A systematic review within the framework of the Cochrane collaboration 2003;28 : 209-18.
10. Canbulat, Nazat et al. A rehabilitation protocol for patients with lumbar degenerative disk disease treated with lumbar total disc replacement. *Archives of Physical Medicine and Rehabilitation* 2011: 92:670-6
11. Oosterhuis, T. et al. Rehabilitation after lumbar disc surgery. *Cochrane data based system review* 2008;4; CD003007.
12. Sjoliner, PO., Nota, DF. Early return to work after following an aggressive rehabilitation program initiated one day after spine surgery. *Journal of Occupational Rehabilitation* 1996;4(4); 211-28.
13. Puolakka, K., Ylinen, J., Hakkinen, A. Risk factors for back pain-related loss of working time after surgery for lumbar disc herniation; a 5 years follow-up study. *European spine journal* 2008;17(3); 386-92.



## ТҮЙІНДЕМЕ

Farid Yudoyono (M.D.)<sup>1</sup>, Muhammad Zafrullah Arifin (M.D., Ph.D.)<sup>1</sup>, Farida Arisanti (M.D.)<sup>2</sup>, Shin Dong Ah (Prof., M.D.)<sup>3</sup>

Department of Neurosurgery, Faculty of Medicine Universitas Padjadjaran-Dr Hasan Sadikin General Hospital, Bandung, Jawa Barat, Indonesia<sup>1</sup>

Department of Physical Medicine and Rehabilitation, Faculty of Medicine Universitas Padjadjaran-Dr Hasan Sadikin General Hospital, Bandung, Jawa Barat, Indonesia<sup>2</sup>

Yonsei University College of Medicine, Seoul. Korea: Spine and Spinal cord Research Institute, Yonsei University College of Medicine<sup>3</sup>

### **БІРЖАҚТАМАЛЫҚ ІШІНАРА ГИМЕЛАМИНЕКТОМИЯ ЖӘНЕ ДИСКЭКТОМИЯ КЕЗІНДЕ ОМЫРТҚАНЫҢ БЕЛ АУМАҒЫНЫҢ ДИСК ЖАРЫҒЫ БАР ПАЦИЕНТТЕРДІҢ АУРУХАНАДА ЖАТУ ҰЗАҚТЫҒЫ МЕН ОПЕРАЦИЯ УАҚЫТЫН АЗАЙТУ**

**Мақсаты.** Омыртқаның бел аумағының диск жарығы кезінде біржақтамалық ішінара гемиламинэктомия (UPHL) арқылы дискэктомия техникасының мүмкіндігін ұсыну және фораминалды локализациялы омыртқаның бел аумағының диск жарығы кезіндегі тиімділігін көрсету.

**Әдістері.** 2012 жылдың сәуірі мен маусымы аралығында біржақтамалық ішінара гемиламинэктомия әдісімен омыртқаның бел аумағы дискісінің 24 жарығына операция жасалды.

**Нәтижелері.** Біржақтамалық ішінара гемиламинэктомия алған 24 пациенттің 14-і ер кісі, 10-ы әйел (1,4: 1), орта жас 54 жасты құрады (21-68 жас), зақымдалу деңгейіне қатысты – 2 пациентте Th 12 L 1 деңгейінде, 12 пациентте L 4-5 деңгейінде, 2 пациентте L 3-4 және 6 пациентте L5-S1. Барлық жағдайларда дуральды қапшық немесе түбіршіктердің зақымдалуынсыз омыртқааралық диск жарығы толығымен алынып тасталынды. Неврологиялық статуста барлық топтарда жақсару байқалды, тек неврологиялық статусы болмашы ғана өзгерген үш пациенттен өзге. Операция ұзақтығы орта есеппен 179 минутты құрады, емделуге жатқызу

күнінің ұзақтығы 5 күн. Барлық топтарда орта есеппен 6 ай бақылау мерзімінде операциядан кейінгі кезеңде омыртқаны қозғаушы сегменттердің тұрақсыздығы белгілері анықталмады. Кейінгі кезеңдердегі бақылаудың барлық уақытында диск жарығының қайталану байқалмады.

Робинсон ауруларының нәтижесі шкаласы бойынша: жақсы – 21, сәтсіз – 3.

**Тұжырым.** Біржақтамалық ішінара гемиламинэктомия микрохирургиялық техникамен бірлесі отырып, бел бөлігінің фораминалды диск жарығын алып тастау үшін қажетті кеңістікті қамтамасыз етеді. Омыртқаның бел бөлігі фораминалды диск жарықтары біржақтамалық ішінара гемиламинэктомия арқылы алынып тасталуы мүмкін, бұл омыртқаның бел бөлігінің диск жарығының хирургиясындағы оның алатын орнын көрсетеді және бұл операция уақыты мен емделуге жату мерзімін азайтуға мүмкіндік береді.

**Негізгі сөздер:** омыртқаның бел аумағының диск жарығы, микрохирургиялық біржақтамалық ішінара гемиламинэктомия.

РЕЗЮМЕ

Farid Yudoyono (M.D.)<sup>1</sup>, Muhammad Zafrullah Arifin (M.D., Ph.D.)<sup>1</sup>, Farida Arisanti (M.D.)<sup>2</sup>, Shin Dong Ah (Prof., M.D.)<sup>3</sup>

Department of Neurosurgery, Faculty of Medicine Universitas Padjadjaran-Dr Hasan Sadikin General Hospital, Bandung, Jawa Barat, Indonesia<sup>1</sup>

Department of Physical Medicine and Rehabilitation, Faculty of Medicine Universitas Padjadjaran-Dr Hasan Sadikin General Hospital, Bandung, Jawa Barat, Indonesia<sup>2</sup>

Yonsei University College of Medicine, Seoul. Korea: Spine and Spinal cord Research Institute, Yonsei University College of Medicine<sup>3</sup>

## УМЕНЬШЕНИЕ ПРОДОЛЖИТЕЛЬНОСТИ ОПЕРАЦИИ И КОЙКО ДНЕЙ НА ФОНЕ ОДНОСТОРОННЕЙ ЧАСТИЧНОЙ ГЕМИЛАМИНЭКТОМИИ И ДИСКЭКТОМИИ У ПАЦИЕНТОВ С ГРЫЖЕЙ ДИСКА ПОЯСНИЧНОГО ОТДЕЛА ПОЗВОНОЧНИКА

**Цель.** Представить возможности техники дискэктомии при грыже диска поясничного отдела позвоночника через одностороннюю частичную гемиламинэктомию (UPHL) и продемонстрировать эффективность при грыжах диска поясничного отдела позвоночника с фораминальной локализацией.

**Методы.** С апреля 2012 года по июнь 2012 года, были прооперированы методом односторонней частичной гемиламинэктомии 24 грыжи диска поясничного отдела позвоночника.

**Результаты.** Из 24 пациентов, перенесших одностороннюю частичную гемиламинэктомию – мужчин – 14, женщин – 10 (1,4: 1), средний возраст составил 54 года (21-68 лет), относительно уровня поражения – у 2-х пациентов на уровне Th 12 L 1, у 12 пациентов на уровне L 4-5, у 2-х пациентов L 3-4, и у 6-и пациентов L5-S1. Во всех случаях, грыжа межпозвоночного диска была удалена полностью, без повреждений дурального мешка или корешков. В неврологическом статусе отмечалось улучшение во всех группах, кроме трех пациентов у которых неврологический статус изменился незначительно. Средняя длительность операции составила

179 минут, длительность госпитализации 5 дней. В послеоперационном периоде не было выявлено признаков нестабильности позвоночнодвигательных сегментов в период наблюдения в среднем 6 месяцев во всех группах. Рецидивов грыжи диска не отмечалось за все время последующего наблюдения. По шкале исхода заболевания Робинсона: удачно – 21, неудачно – 3.

**Заключение.** Односторонняя частичная гемиламинэктомию в сочетании с микрохирургической техникой обеспечивает достаточное пространство для удаления фораминальной грыжи диска поясничного отдела. Фораминальные грыжи диска поясничного отдела позвоночника могут быть удалены путем односторонней частичной гемиламинэктомии, что демонстрирует ее роль в хирургии грыжи диска поясничного отдела позвоночника, и это может уменьшить операционное время и пребывание в больнице.

**Ключевые слова:** грыжа диска поясничного отдела позвоночника, микрохирургическая односторонняя частичная гемиламинэктомию.